

Ultrasound-guided transbronchial mediastinal cryobiopsy

Background

Endobronchial ultrasound-guided transbronchial needle aspiration (EBUS-TBNA) has been a cornerstone in the diagnosis of mediastinal and hilar lymphadenopathy. Despite its widespread use, EBUS-TBNA has limitations, particularly in obtaining sufficient tissue samples for certain diagnoses such as lymphoma, granulomatous diseases, and other conditions requiring extensive histological and molecular analysis. EBUS-guided transbronchial mediastinal cryobiopsy (EBUS-TBMC) has emerged as a promising alternative, capable of providing larger tissue samples with diagnostic yields of up to 100%.

The endoscopic approach through the tracheobronchial tree or esophagus via EBUS-TBNA or endoscopic ultrasound (EUS) is known to have several advantages for mediastinal adenopathy:

1. **ability to access multiple lymph node stations.**
2. **ability to detect and sample lymph nodes even those <10 mm in size.**
3. **high diagnostic yield that is equivalent to mediastinoscopy.**

However, while EBUS-TBNA has an excellent yield with primary thoracic malignancy and metastatic lesions, its performance with other diagnoses varies. In 2020, human use of EBUS-TBMC was first reported in a 19-year-old patient with mediastinal seminoma, after an initial non-diagnostic EBUS-TBNA. Ever since, studies have investigated potential advantages of combined EBUS-TBNA and TBMC compared to standard EBUS-TBNA alone. Especially in challenging scenarios where a histopathological evaluation and assessment of the surrounding tissue structure is necessary, cryobiopsy was found to be extremely advantageous for diagnosis.

Some interventional pulmonologists use a high-frequency needle knife to create an incision in the tracheobronchial wall adjacent to the mediastinal lesion before inserting the cryoprobe, while others use a needle to create a pathway to the target area. There are also variations in the use of endoscopic or ultrasound imaging for guidance, showing the need to streamline the approach of combined EBUS-TBNA and TBMC so that future published trials can be compared easily.

Methods

This medical insight aims to shed light on two reviews by Romero and Kho¹ and Ariza Prota et al.² who discuss ultrasound-guided mediastinal cryobiopsy with the 1.1 mm single-use cryoprobe (Erbe Elektromedizin GmbH) and provide a framework for standardizing the procedure to optimize outcomes and minimize complications. Romero and Kho conducted a systematic literature review highlighting efficacy of EBUS-TBMC for evaluation of both malignant and benign mediastinal lesions. In addition to reviewing the current literature, Ariza Prota et al. share their own clinical experience and methodology by systematically describing the four-step Ariza-Pallarés method for performing safe, fast, and effective endobronchial ultrasound-guided mediastinal cryobiopsy.

Results

Indications and contraindications for EBUS-TBMC

In their publication, Ariza Prota et al. determine indications and contraindications for performing a mediastinal cryobiopsy, stating the contraindications of EBUS-TBMC to be the same as for EBUS-TBNA.

Indications for EBUS-TBMC	Contraindications for EBUS-TBMC
Suspected lymphoproliferative disorders	Current or recent myocardial ischemia
Suspicion of benign granulomatous processes	Severe hypoxemia
Metastases from other non-pulmonary or infrequent tumors	Hemodynamic instability
Non-diagnostic EBUS-TBNA	Severe pulmonary hypertension
Necrotic lymph nodes/lesions	Poorly controlled heart failure
NSCLC stages III–IV (immunohistochemical and molecular analysis)	Chronic obstructive pulmonary disease (COPD)/asthma exacerbation
	Life-threatening dysrhythmias
	Patient on anticoagulation/dual antiplatelet therapy
	Clotting abnormalities
	Intolerance to sedation/anesthesia
	Vascular image patterns of grade III–IV on the ultrasound

Four-step Ariza-Pallarés method

Since EBUS-TBMC shares initial procedural steps with EBUS-TBNA and a combination of both approaches has yielded promising results in previous studies, Ariza Prota et al. propose a standardized approach, called Ariza-Pallarés method. The approach features both, EBUS-TBNA and EBUS-TBMC, and is applicable to transbronchial and transesophageal access routes. The four steps include:

1. Planning:

- Consider location, size, and vascularity of the lesion or lymph node and ensure appropriate preparation.
- Ariza Prota et al. state that mediastinal cryobiopsy can be performed in all lymph node stations and rank the lymph node stations accessibility from easiest to most challenging as follows: 11L, 11Ri, 7, 11Rs, 4R, 2L, 2R, 10R, 10L, 3p, and 4L.

2. Puncture:

- Employ ultrasound imaging with Doppler mode to avoid any vessels.
- Choose the location with the thinnest mucosa and lymph node capsule and avoid any cartilages before performing the TBNA.
- Perform first conventional TBNA: use either a high-frequency needle knife or a conventional needle to create an access path to the target lesion. The suggested standard practice is to make 8–12 passes.

3. “The Tunnel”:

- Locate the trace left by the TBNA in the lymph node from the previous puncture.
- Perform second conventional TBNA: tunnelling involves creating a pathway through the mucosa, submucosa, and capsule of the lymph node to ensure easy insertion of the cryoprobe. The suggested standard practice is to make 8–12 passes, until it can be confirmed that the capsule has been successfully broken.

4. The Cryobiopsy:

- Employ ultrasound imaging and identify the tunnel and broken capsule as well as any vessels.
- Apply the 1.1 mm SU cryoprobe (Erbe Elektromedizin GmbH) to the lesion under EBUS guidance.
- Confirm the correct position of the cryoprobe in the lymph node by using ultrasound imaging and Doppler mode.
- Perform three cryobiopsies per station (distally, medially, and proximal to the capsule). The “fanning” technique can be performed. Freeze 3–5 s.

During this step, make sure to:

- Keep lever of the EBUS bronchoscope in neutral position before taking the scope out with the cryobiopsy sample
- Always keep the tip of the cryoprobe image on the ultrasound.
- Keep the pedal close to your foot and keep it pressed until the sample is secured.

Note: Depending on the needle, more than two insertions might be necessary.

Safety

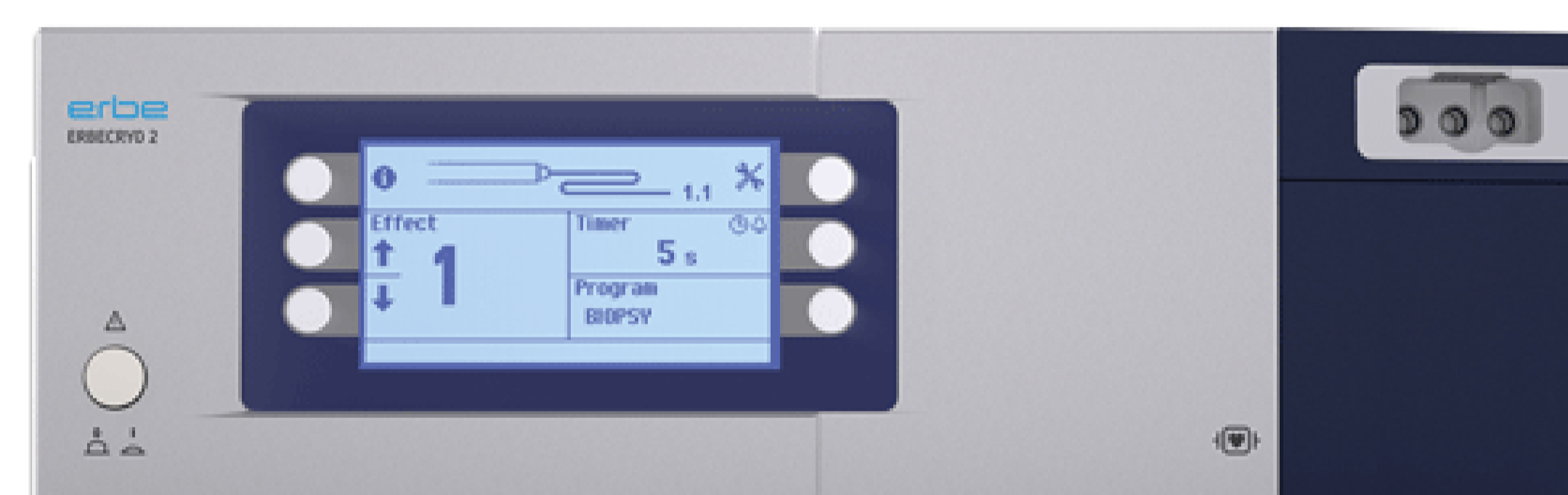
For 20 years, bronchoscopy with EBUS-TBNA has been accepted worldwide to be minimally invasive and safe. With the addition of a cryoprobe biopsy tool in 2020 and the subsequent possibility of yielding larger specimens, the risk of larger defects created in the airway wall increased. Complications in the review include airway pneumothorax, pneumomediastinum and mediastinitis with the most commonly reported complication being bleeding. However, most bleeding is mild and can be easily managed, and self-limiting pneumothorax and pneumomediastinum are observed with a risk of 1%. Thus, in line with EBUS-TBNA, EBUS-TBMC can be considered a safe approach with a clearly positive benefit-risk profile.

Implications and recommendations

The larger and more intact tissue samples obtained through EBUS-TBMC provide a clearer histological architecture, facilitating more accurate diagnoses, especially in conditions where traditional EBUS-TBNA may fall short. The method’s ability to provide sufficient tissue for comprehensive molecular and genetic analysis is a significant advancement in the management of complex mediastinal pathologies. However, the procedure’s complexity and the requirement for specialized equipment and training are challenges that need addressing. Standardizing the procedure, as suggested in the four-step Ariza-Pallarés approach, is crucial for broader clinical adoption and to ensure consistent, safe, and effective outcomes.

Products

Ariza Prota et al. use the flexible single-use 1.1 mm cryoprobe (Erbe Elektromedizin GmbH). Romera and Kho mention the use of both, the single-use 1.1 mm and the single-use 1.7 mm cryoprobe (Erbe Elektromedizin GmbH) in their review.



*Flexible cryoprobe for single use, 1.1 mm
(20402-401)*



*Flexible cryoprobe for single use, 1.7 mm
(20402-410)*

References

- 1 Romero AO, Kho SS. Transbronchial mediastinal cryobiopsy – literature review and practice recommendations. *AME Med J* 2024;9:35; DOI: [10.21037/amj-23-120](https://doi.org/10.21037/amj-23-120)
- 2 Ariza-Prota M, Pérez-Pallarés J, Fernández-Fernández A et al. EBUS-guided transbronchial mediastinal cryobiopsy in the diagnosis of mediastinal lesions: safety, feasibility and diagnostic yield – experience in 50 cases. *ERJ Open Res* 2023: 448–2022, DOI: [10.1183/23120541.00448-2022](https://doi.org/10.1183/23120541.00448-2022)